

## Infected transcartilaginous ear piercings. A case report and review of the literature

### Pericondritis del pabellón auricular por piercings. Reporte de un caso clínico y revisión de la literatura

Javier Rodríguez,<sup>1,2,\*</sup> Natalie Thone,<sup>2,3</sup> Josefina Duque<sup>4</sup>, Rocío Brañes<sup>4</sup>

#### Abstract

**Background:** transcartilaginous perforations have become a prominent practice among adolescents and young adults in recent years, which are associated with an increased risk of complications since it is frequently performed without sterile technique and by unqualified individuals. The transgression of the integrity of the skin and cartilage of the ear favors infections such as cellulitis, chondritis, perichondritis or abscesses that can cause serious deformities. **Methods:** we present a clinical case compatible with a perichondritis secondary to ear perforations with three abscesses. **Results:** the three abscesses were drained with sterile technique and successfully managed with outpatient antibiotic treatment. In relation to the pathophysiology, the trauma in the auditory pavilion produces the extraction of the adjacent perichondrium, causing devascularization of the cartilage and microfractures, which together with the transgression of the skin, increase the susceptibility to infection. In addition, subpericardial bleeding and inflammatory reaction decrease the blood supply, which limits the immune response and the effectiveness of antibiotics. In some cases, incision and drainage are required. The signs of perichondritis include pain, swelling, and erythema of the skin. Clinically, perichondritis can be differentiated from cellulitis of the pinna, in that the first usually does not involve the earlobe. The fluctuating swelling leads us to an abscess. **Conclusions:** the administration of broad-spectrum antibiotics should be immediately administered and include coverage for *Pseudomonas aeruginosa* since it is responsible for the majority of post-perforation cartilage infections (up to 95% of cases). Due to the increase of post-perforation infectious complications, all physicians should be familiar with its diagnosis and treatment.

**Keywords:** ear piercing; perichondritis; transcartilaginous ear perforations; pseudomonas infections.

Fecha de envío: 4 de diciembre de 2018 - Fecha de aprobación: 30 de mayo de 2019

#### Introduction

Transcartilaginous ear piercings (TEPs) have become a prominent practice among adolescents and young adults in the last years, and unlike the earlobe piercings, TEPs are associated with an increased risk for the patients (Keene et al., 2004; Perry & Sosin 2014; Sosin et al., 2015). It is frequently performed without sterile technique by unqualified individuals, and inadequate aftercare instructions (without an explanation of potential complications) (Keene et al., 2004; Lee & Gold 2011). Transgression of skin and cartilage integrity favors potential infections like ear cellulitis, chondritis, perichondritis or abscesses; such complications may cause severe ear deformities (Sosin et al., 2015). It is important to determine the best approach to deal with infections resulting from TEPs. We present a case report of a young adult with a pinna perichondritis secondary to ear piercings managed with outpatient antibiotic treatment.

#### Case presentation

A 21-year-old female patient with no medical or surgical history, with 3 TEPs on scapha performed four weeks ago in a piercing studio (for the procedure, we wiped the ear with 70% alcohol and the cartilage was penetrated with a sharp, hollow sterile needle). The patient arrived at our department with a 4-day history of upper right ear pain and erythema of the scaphoid fossa associated with localized swellings in the piercing sites. There was no history of fever or any other symptoms. Vital signs were stable. Upon ear examination, we noted three small swellings on the ear cartilage with mild pus discharge about the piercings, in addition to extensive redness on the upper ear (Figure 1). The ear was exquisitely tender to palpation, without cervical lymphadenopathies. Due to these signs, we suspected an auricular perichondritis and three little abscesses.

(1) Department of Surgery, Facultad de Medicina, Pontificia Universidad Católica de Chile, Santiago, Chile.

(2) Department of Medical Education, Facultad de Medicina, Pontificia Universidad Católica de Chile, Santiago, Chile.

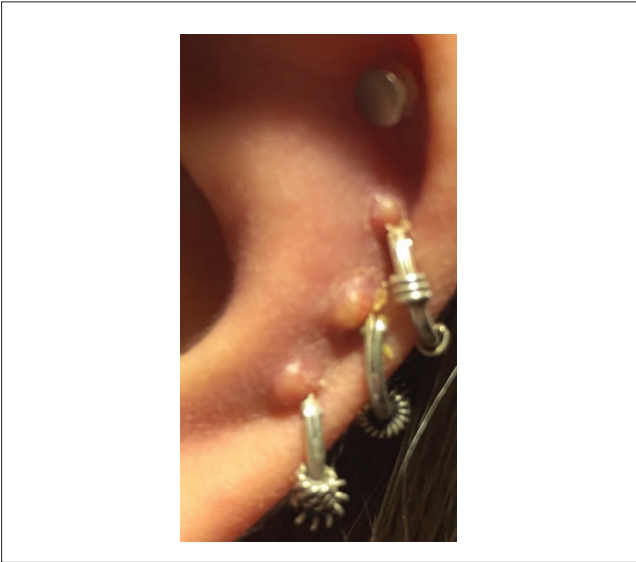
(3) Department of Otorhinolaryngology, Facultad de Medicina, Pontificia Universidad Católica de Chile, Santiago, Chile.

(4) Medical School, Facultad de Medicina, Pontificia Universidad Católica de Chile, Santiago, Chile.

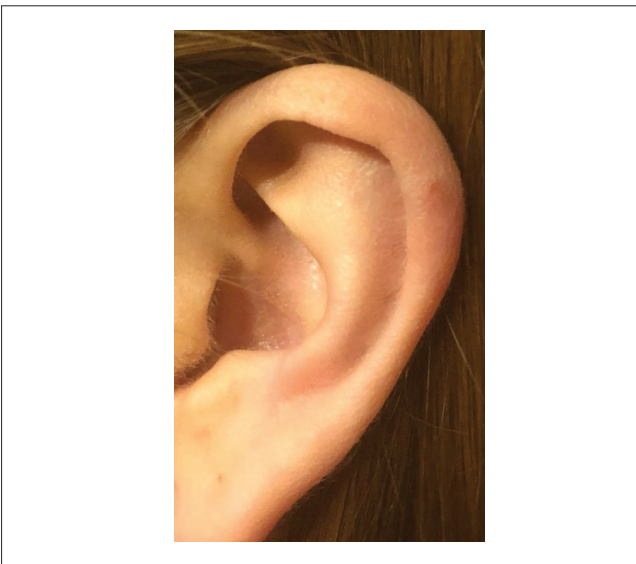
\* Corresponding author: [jirodri4@uc.cl](mailto:jirodri4@uc.cl)



The three hoops were removed using sterile technique, drained the abscesses and a 10-day course of levofloxacin (750 mg once daily) was prescribed to cover for empiric *Pseudomonas aeruginosa* and *Staphylococcus aureus*. The patient was monitored daily and educated in alarm symptoms to consult in emergency service. Four days after the first visit, and having received levofloxacin, the erythema and swellings in the right ear had decreased. There was no cosmetic deformity of the pinna at follow up (Figure 2).



**Figure 1:** Three small swellings on the helix of the left pinna with mild pus discharge in relation to the piercings. Extensive redness on cartilaginous pinna.



**Figure 2:** Left pinna after treatment, without sign of cosmetic deformity.

## Discussion

The practice of body piercing (BP) in adolescents and young adults, principally high TEPs (in the upper third of the pinna), have become increasingly popular and prevalent in the last 20 years (Hanif et al., 2001; Bone et al., 2008; Liu & Chokkalingam, 2013; Sosin et al., 2015). TEPs have been reported as the third most common body piercing other than the earlobe (Bone et al., 2008). Unfortunately, cartilage ear piercing is frequently performed without sterile technique and by unqualified individuals that are unaware of the severity of potential complications after the procedure (Keene et al., 2004; Perry & Sosin, 2014). Before the procedure, the ear commonly is disinfected with isopropyl alcohol (like in the case reported) or benzalkonium chloride, which are ineffective against the *Pseudomonas* species and spore-forming bacteria (Stewart et al., 2006; Lee & Gold 2011; Perry & Sosin 2014).

Regardless of the technique, the localized trauma on the pinna produces extraction of the adjacent perichondrium (which causes cartilage devascularization) and microfractures, which together with the transgression of the skin, increase the susceptibility to infection (Sosin et al., 2015). Also, the subperichondrial bleeding and inflammatory reaction decrease an already limited blood supply of the cartilage (Perry & Sosin, 2014; Sosin et al., 2015). The avascular environment limits the immune response and the effectiveness of antibiotics, so in some cases, incision and drainage are required (ideally obtaining cultures and sensitivities to guide the optimal antibiotic therapy) (Lee & Gold, 2011; Perry & Sosin, 2014; Sosin et al., 2015).

A recent systematic review confirms that post piercing infectious complications are increasing, and identifies that adolescent and young adult females most frequently develop post piercing perichondritis (Sosin et al., 2015). Furthermore, the use of piercing guns and exposure of the wound to fresh water, water in swimming pools or hot tubs after the procedure, may additionally increase the risk of infection (Keene et al., 2004; Fisher et al., 2005; Lee & Gold, 2011). The lag time between the onset of symptoms and medical attention is about one week, but a delay greater than five days since the beginning of the symptoms is more likely to result in hospitalization (Sosin et al., 2015). Signs of perichondritis or chondritis in patients with an embedded earring are similar (these include pain, swelling and erythema of the overlying skin) and fluctuant swelling indicate an abscess that we should drain (typically associated with chondritis) (Fisher et al., 2005; Sosin et al., 2015). Clinically, perichondritis can be differentiated from cellulitis of the pinna, in that the first usually does not involve the earlobe (Kullar & Yates, 2015).

Once the clinical diagnosis of a post piercing infection has been made, antibiotic therapy should be administered immediately, since perichondritis can result in permanent ear deformity (cauliflower ear) (Hanif et al., 2001; Stewart et al., 2006; Lee & Gold, 2011; Liu & Chokkalingam, 2013; Perry & Sosin, 2014). It is relevant to select a broad spectrum antibiotic that covers *Pseudomonas* and *Staphylococcus* species and includes oral fluoroquinolones (e.g., levofloxacin) in adolescents and adults (Lee & Gold, 2011; Liu & Chokkalingam, 2013; Perry & Sosin, 2014; Sosin et al., 2015). It is also necessary to remove the foreign body from the pinna. *Pseudomonas aeruginosa* is responsible for most post piercing cartilage infections (in 87 up to 95% percent of cases) (Fisher et al., 2005; Liu & Chokkalingam, 2013; Sosin et al., 2015). Infections may require prolonged antimicrobial therapy, plus incision and drainage (due to the poor blood supply of the ear cartilage). When abscesses are present, they should be drained promptly and cultured to reduce the risk of cartilage damage induced by pressure and provides a microbiological diagnosis and sensitivity results (Sosin et al., 2015). However, even with timely and adequate treatment, these infections may result in cartilage necrosis and deformity of the pinna (Lee & Gold, 2011).

In patients without fluctuant swelling, outpatient antibiotic treatment may be attempted, with daily observation (and drainage or debridement if necessary) (Perry & Sosin, 2014). Nonetheless, if the patient has no response to oral antibiotics within 24 hours, they must be hospitalized for intravenous antibiotics and eventually surgical drainage (Perry & Sosin, 2014; Sosin et al., 2015).

## Conclusion

Post-piercing infectious complications are increasing. All physicians should be familiar with its diagnosis and treatment. Signs of perichondritis or chondritis include pain, erythema of the overlying skin and swelling. A fluctuant swelling indicates an abscess that we should drain.

*Pseudomonas* and *Staphylococcus* species are the most frequently isolated pathogens on post piercing infections. Treatment should be administered immediately after diagnosis to avoid devastating complications. It is important to select a broad spectrum antibiotic that covers these bacteria, and that includes oral fluoroquinolones (eg, Levofloxacin) in adolescents and adults.

In the absence of fluctuant swelling, outpatient antibiotic treatment may be attempted, with daily observation. If the patient has no response to oral antibiotics within 24 hours, they must be hospitalized.

With this report, we want to raise awareness about the risk of infection and deformity of the ear after ear piercing. We also want to report a case of infected TEPs managed with outpatient antibiotic treatment with excellent response.

## Patient consent

Patient consent was obtained for the publication of this article and associated images

## References:

- Bone A, Ncube F, Nichols T & Norman D.N. (2008). Body Piercing in England: A Survey of Piercing at Sites Other than Earlobe. *British Medical Journal: BMJ* **336**, 1426–28.
- Fisher C, Kacica M.A & Bennett N.M. (2005). Risk Factors for Cartilage Infections of the Ear. *American journal of preventive medicine* **29**, 204–9.
- Hanif J, Frosh A, Marnane C, Ghufloor K, Rivron R & Sandhu G.(2001). Lesson of the Week: 'High' Ear Piercing and the Rising Incidence of Perichondritis of the Pinna. *British Medical Journal: BMJ* **323**, 400.
- Keene W, Markum A & Samadpour M. (2004). Outbreak of *Pseudomonas Aeruginosa* Infections Caused by Commercial Piercing of Upper Ear Cartilage. *Journal of the American Medical Association* **291**, 981–85.
- Kullar P & Yates P. (2015). Infections and Foreign Bodies in ENT. *Surgery* **33**, 593–99.
- Todd L. C. & Gold W. (2011). Necrotizing *Pseudomonas* Chondritis after Piercing of the Upper Ear. *Canadian Medical Association journal = journal de l'Association medicale Canadienne: CMAJ* **183**, 819–21.
- Liu, Z. W. & Chokkalingam P. (2013). Piercing Associated Perichondritis of the Pinna: Are We Treating It Correctly?. *Journal of Laryngology and Otology* **127**, 505–8.
- Perry, Arthur W & Sosin M. (2014). Reconstruction of Ear Deformity from Post Piercing Perichondritis. *Archives of Plastic Surgery* **41**, 609–12.
- Sosin M, Weissler J, Pulcrano M & Rodriguez E. (2015). Transcartilaginous Ear Piercing and Infectious Complications: A Systematic Review and Critical Analysis of Outcomes. *The Laryngoscope* **125**, 1827–34.
- Stewart, Gail M, Thorp A & Brown L. (2006). Perichondritis -- A Complication of High Ear Piercing. *Pediatric Emergency Care* **22**, 804–6.